

A female with 46, XY Disorder of Sexual Development with normal SRY gene sequence: A case report

Mehdi Agha Gholizadeh¹, Afsaneh bazgir¹, Faezeh Sarvar¹, Zahra Pakzad^{1*}

1. Department of Medical Genetics, Fardis Central Lab, Alborz, Iran

Article Type:

Case Report

Article History:

Received: 5 Dec. 2018

Revised: 30 Jan. 2019

Accepted: 02 Feb. 2019

*Correspondence:

Zahra Pakzad,
Department of Medical
Genetics, Fardis Central
Lab, Alborz, Iran

dr_zahrapakzad@yahoo.com



Abstract

Background and objectives: Disorders of sex development (DSD) are a medical condition that affects the normal process of sexual development. Various of the genes needed for gonad development have been identified by investigation of patients with disorders sex development (DSD). Phenotypes of patients with 46,XY DSD range from agonadism in female phenotype with complete external genitalia to male phenotype with testicular regression. Individuals with 46, XYagonadism show a wide range of clinical features and in some cases, there is not a clear diagnosis for these patients. We presented the clinical and molecular study a patient with 46, XY female without gonadal tissue.

Case presentation: A 27-year-old female was attended to our center because of primary amenorrhea. Ultrasonography did not show gonadal tissue including Mullerian structures, uterus, and Wolffian structures. Also, the patient had not streak gonad. We performed cytogenetic study and molecular analysis, including automated sequencing of the entire coding region of SRY gene, in the patient with agonadism. Our result showed 46, XY karyotype. Also, we noticed that molecular mutations in SRY are not identified as a cause of DSD female without a gonadal tissue. Laboratory examination showed that this case is a unique patient with 46, XY female agonadism that has no association with previously described.

Conclusion: The present case was a patient with 46, XYagonadism without hormonal or kidney defect and we did not detect mutation in SRY gene. To our knowledge, this case is a unique patient with 46, XYagonadism that has no association with previously described. So this case would be helpful for clinicians to assess 46, XY female patients without gonadal tissue.

Keywords: Disorder of sexual development, XY female Agonadism, SRY gene

Introduction

Disorders of sex development (DSD) are a congenital condition in which processes of chromosomes, gonads, and phenotypic sex is atypical (1, 2). There are several types of DSDs and their effect varies on the internal and external reproductive organs and in some

cases, it is not probably to make a definite diagnosis of the underlying condition. The overall incidence of 46, XY DSD is estimated to be 1 in 20,000 births (3). The inability of the bipotential gonads to differentiate can result in 46, XY DSD (4). The 46, XY DSD female refers to phenotypic females with a male genotype (5). Subjects with 46, XY

Copyright© 2018, Jorjani Biomedicine Journal has published this work as an open access article under the terms of the Creative Commons Attribution License (<http://creativecommons.org/licenses/by-nc/4.0/>) which permits non-commercial uses of the work while it is properly cited.



DSD have been diagnosed mainly through clinical and usually identified during an examination for delayed puberty or primary amenorrhea. 46, XY gonadism characterized as lack of secondary sexual development, normal female external genitalia and have not gonadal structures and internal genitalia that represents an exceptional clinical finding (6). Subjects with 46,XY gonadism show a wide range of clinical features from phenotypic females with primary amenorrhea to phenotypic males and may display craniofacial, cardiac, renal and limb defects, as well as mental retardation that their condition is different from that of feminizing testis syndrome and Swyer syndrome individuals (7). In this study, we report a patient with 46, XY female that unlike normal SRY gene and normal hormonal balance, she is completely gonadism with no female or male gonadal structures.

Many of genes required for gonad development. Sex-determining region Y (SRY) gene play a key role in testis-determining pathway and in 10%-20% of individuals with 46,XY female a mutation found in the SRY gene (8). So, we report the molecular analysis of the coding region of SRY gene in one patient with 46, XY female gonadism. Our report adds clinically and hormonal balance to previous findings

showing no mutation in the SRY gene in this group of disorders.

Case report

A 27-year-old female presented to her care provider due to primary amenorrhea. On Physical, the patient was found to have a female phenotype, a height of 187 cm. The breast was minimal, the external genitalia was normal female with labia minor agenesis and a vagina with a depth of 5cm. Transabdominal ultrasonography did not show gonadal tissue and uterus, ovaries and testes also were absent. Also, ultrasound did not detect probably streak gonads. The patient presented with normal mental development and had no dysmorphic features. Laboratory evaluation showed that estradiol levels (29 pg/ml), levels of follicle-stimulating hormone (19.8 mIU/ml), the serum level of luteinizing hormone (12.3 mIU/ml) and testosterone levels (0.21 ng/ml) were within the normal range for women. The rest of the level of hormones also were the normal female range (Table 1).

The findings show the normal function of the adrenal. Phosphate and thyroid function tests were also normal. Serum sodium was 140 meq/l and potassium was 4.3 meq/l.

Patient's whole blood was cultured and incubated at 37°C for 69 hours. Then after harvesting of nucleated cells, G-banding karyotype of the chromosomes was performed.

The karyotype result was 46,XY female. So for determining SRY gene on Y chromosome, we performed PCR using Test-SRY kit (TestGene, Russia) according to manufactures structures. Genomic DNA was extracted from a peripheral blood sample according to standard protocols. Amplification of SRY gene was performed by Polymerase Chain Reaction (PCR). PCR cycling conditions were 95 °c (5 min), 95 °c (1min), 60 °c (1 min), 72 °c (40 s) for 35 cycles, followed by a final extension step at 72 °c (5 min). After determining of SRY gene, direct sequencing of PCR product (675bp) of SRY amplification was carried out using 3130 automated DNA sequence (Applied Biosystems). We sequenced the whole exon of SRY gene. The sequencing was performed with both sense and antisense primers to confirm the results. Then, SRY sequence was analyzed by sequencing analysis software, version 5.3.1.

Table 1. Results of the hormonal and serum evaluation

Test	Patients value	Female reference range (follicular phase)
Follicle-stimulation hormone (FSH)	19.8	2.55-19.92 mIU/ml
Luteinizing hormone (LH)	12.3	1.8-12.9 mIU/ml
Testosterone	0.21	0.13-0.53 ng/ml
Estradiol	29	21-251 pg/ml
Cortisol	16.5	3.7-19.4 ug/dl
Progesterone	0.1	0.1-0.3 ng/ml
Prolactine	13.8	5.1-26.3 ng/ml
Dehydroepian drosterone sulfate	202.8	96-512 ug/ml
Cholestrol	132	<200 mg/dl
Calcium	9.0	8.6-10 mg/dl
Thyroid Stimulating Hormone	2.49	0.3-4.5 uIU/ml
T3	124.0	76-220 ng/dl
T4	7.87	4.5-12.6 ug/dl

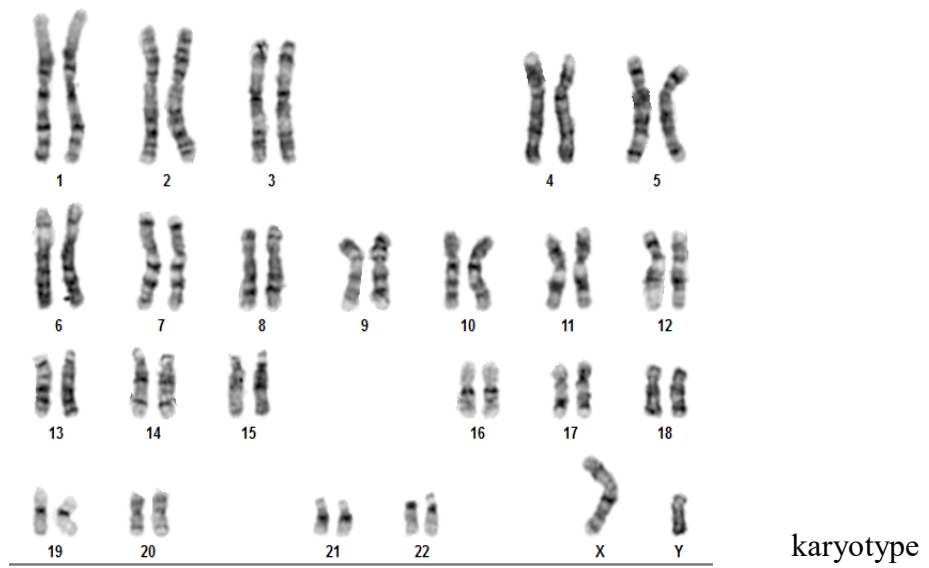


Figure 1: G-banding revealed a 46,XY.

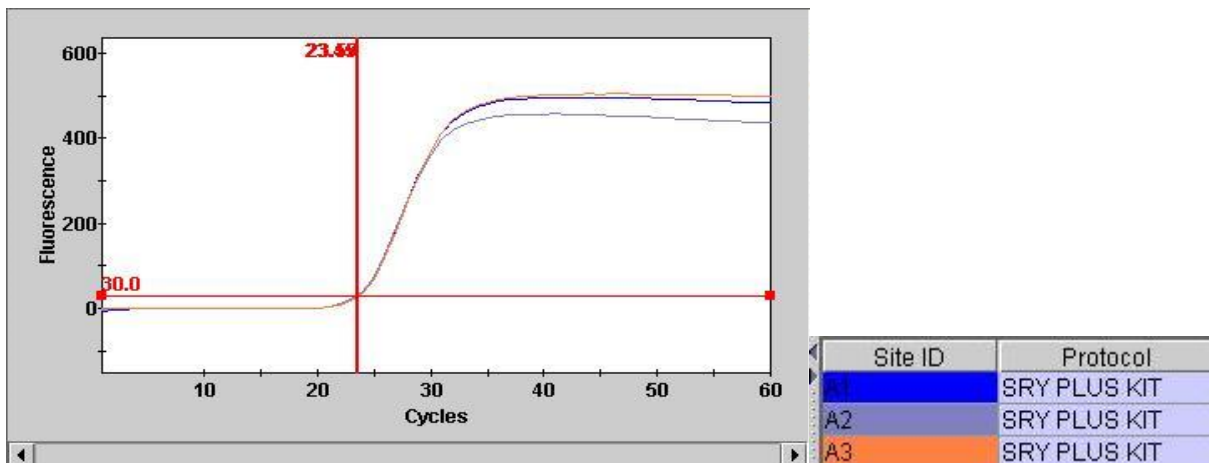


Figure 2: Amplification of SRY gene in triplicate. For determining SRY gene on Y chromosome, we performed PCR.

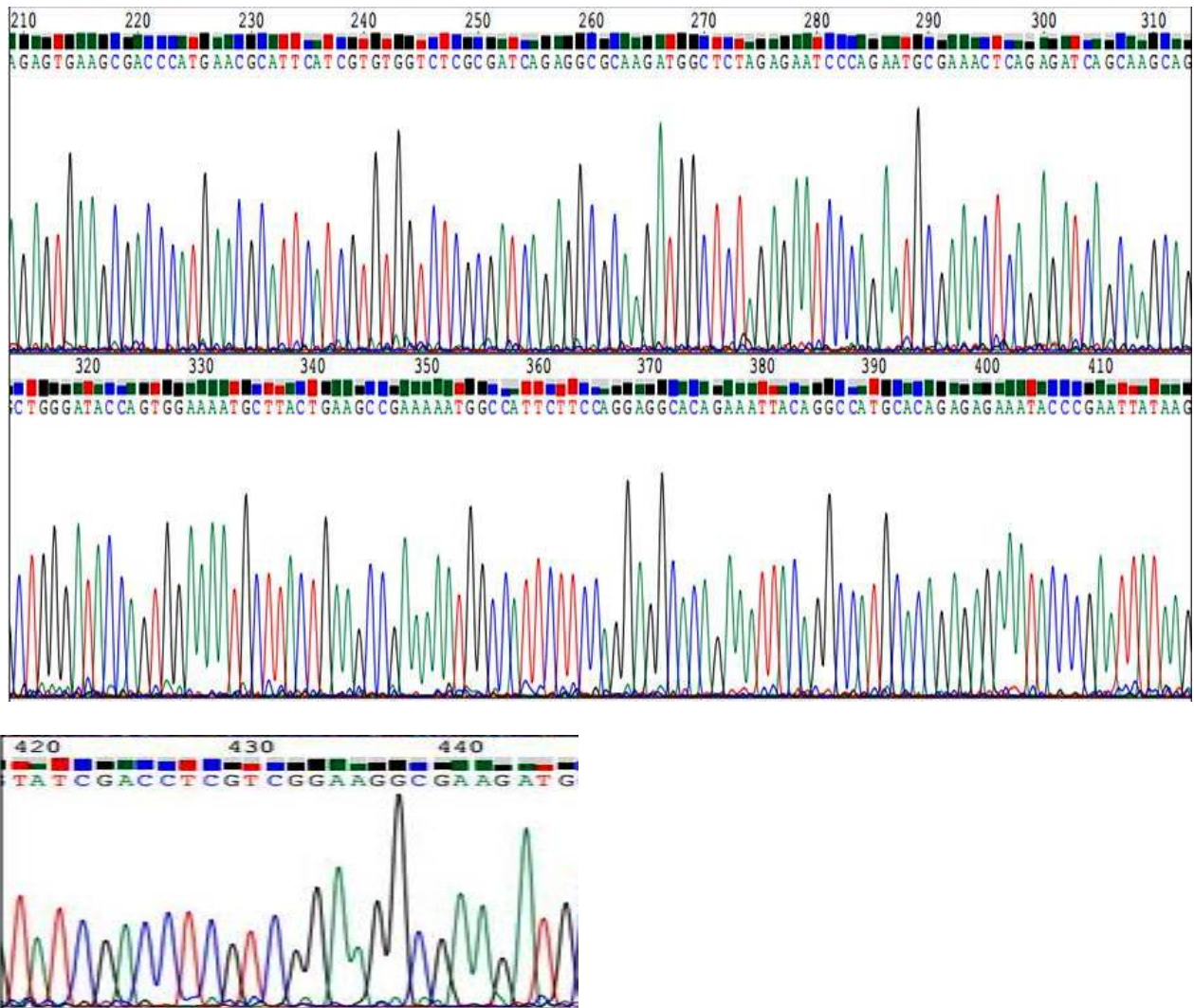


Figure 3: Partial electropherograms of the SRY gene. This area is the highly conserved high mobility group box-coding region of the gene. No mutations were found in the complete exon region of SRY in our patient.

Discussion

Bipotential gonads drive from the urogenital ridge, which contains cell precursors that led to forming the adrenal cortex, gonads, and kidneys (9). The expression of different genes affects in the fate of the bipotential gonad such as SRY, NRF5A1/SF1, DAX1, WT1, and Sox9. Mutations in SRY are a potential

source of defective testicular organogenesis such as XY gonadism. Absence of gonadal tissue has been described in 46, XY subjects with female external indicating the absence of testicular determination and depending on the time at which degenerate during development. In this study, a karyotype revealed that our patient was 46, XY and amplification of SRY

gene was performed by Polymerase chain reaction, indicating our patient has a normal SRY gene (Figure 1-2). We also performed sequence analysis of the complete SRY gene in one case. We did not detect SRY mutation in our patient in SRY exon and HMG-box region (Figure 3). This result is in line with the previous study that showed no mutation detect in SRY gene in this group patients (10). Thus, mutations in other genes such as SOX9, DAX1, WT-1, and SF1 that act a transcription activator downstream of SRY in the testis-determining pathway may result in agonadism. In a study showed that Lhx9 knockout in mice led to defect in forming gonads (11). According to these studies, mutations in LHX9 may be responsible for some cases of isolated agonadism in human. Also, our patient has normal adrenal hormone level. In this regard, recent reports showed that SF1 mutations due to abnormalities of gonadal development in patients with 46, XY DSD without adrenal failure (5). Thus, agonadsim may result from mutation of SF1 gene. Therefore, the SRY gene does not play a significant role in the etiology of the disease in this case. YING-XIA *et al.* showed that patient with agonadism associated with Y-chromosome rearrangement. They also reported that have reduced the expression of USP9Y and UTY genes on the Y chromosome, which might explain phenotype

of agonadism in their patient that the opposite of our patient had a vestigial uterus (12). It is worth mentioning, people with Swyer syndrome have a 46,XY karyotype with typical female external but their uterus and fallopian tubes are normally formed and affected individuals have streak gonads that it can distinguish our patient with Swyer syndrome (13). Also, it can be mentioned that our case is different from Androgen insensitivity syndrome (AIS), because AIS can present with inguinal hernia or labial swelling containing a testis in an apparent 46, XY female infant, and vagina and external genitalia can be normal or just slightly undeveloped (14). Half of all patients with different type of 46, XY DSD have yet to receive a definitive diagnosis and types of 46, XY DSD classifies according to clinical diagnosis based on hormone level and anatomy evaluation (15). The remarkable note is that our patient does not have any hormonal disorder that was reported in previous studies. Therefore, it would help clinicians to the diagnosis of this patient group and distinguish them from other DSDs.

Conclusion

In conclusion, we have presented the report of a patient with 46, XY(+SRY) agonadism female without hormonal or kidney defects did not associate mutations of SRY gene. So this case would be helpful for clinicians to

assess 46, XY female patients without gonadal tissue and distinguish from other 46,XY DSD such as Sywer syndrome.

Acknowledgment:

We thank the patient for her cooperation in the study and would like to thank Dr. Mohamad Javad Gharavi for his scientific and technical support.

Funding source(s)

This work supported by the Fardis Central Laboratory.

Ethics approvals and consent to participate

A written informed consent was obtained.

Conflict of interest

The authors have no conflicts of interest to declare

Authors' contributions

All authors contributed equally to this work

References

1. Hughes IA, Houk C, Ahmed SF, Lee PA, Society LWPE. Consensus statement on management of intersex disorders. *Journal of pediatric urology*. 2006;2(3):148-62.
2. Sullivan CA, Hoffman JD, Safer JD. 17- β -hydroxysteroid dehydrogenase type 3 deficiency: Identifying a rare cause of 46, XY female phenotype in adulthood. *Journal of Clinical & Translational Endocrinology: Case Reports*. 2018;7:5-7.

3. Lee PA, Nordenström A, Houk CP, Ahmed SF, Auchus R, Baratz A, et al. Global disorders of sex development update since 2006: perceptions, approach and care. *Hormone research in paediatrics*. 2016;85(3):158-80.
4. Mota BC, Oliveira LMB, Lago R, Brito P, Canguçu-Campinho AK, Barroso U, et al. Clinical profile of 93 cases of 46, XY disorders of sexual development in a referral center. *International braz j urol*. 2015;41(5):975-81.
5. Mendonca BB, Domenice S, Arnhold IJ, Costa EM. 46, XY disorders of sex development (DSD). *Clinical endocrinology*. 2009;70(2):173-87.
6. Ottolenghi C, Moreira-Filho C, Mendonça BB, Barbieri M, Fellous M, Berkovitz GD, et al. Absence of mutations involving the LIM homeobox domain gene LHX9 in 46, XY gonadal agenesis and dysgenesis. *The Journal of Clinical Endocrinology & Metabolism*. 2001;86(6):2465-9.
7. Zenteno JC, Jiménez AL, Canto P, Valdéz H, Méndez JP, Kofman-Alfaro S. Clinical expression and SRY gene analysis in XY subjects lacking gonadal tissue. *American Journal of Medical Genetics Part A*. 2001;99(3):244-7.
8. Ono M, Harley VR. Disorders of sex development: new genes, new concepts. *Nature Reviews Endocrinology*. 2013;9(2):79.
9. Camats N, Pandey AV, Fernandez-Cancio M, Andaluz P, Janner M, Toran N, et al. Ten novel mutations in the NR5A1 gene cause disordered sex development in 46, XY and ovarian insufficiency in 46, XX individuals. *The Journal of Clinical Endocrinology & Metabolism*. 2012;97(7):E1294-E306.
10. Zenteno JC, Jiménez AL, Canto P, Valdéz H, Méndez JP, Kofman-Alfaro S. Clinical expression and SRY gene analysis in XY subjects lacking gonadal tissue. *American journal of medical genetics*. 2001;99(3):244-7.
11. Birk OS, Casiano DE, Wassif CA, Cogliati T, Zhao L, Zhao Y, et al. The LIM homeobox gene Lhx9 is essential for mouse gonad formation. *Nature*. 2000;403(6772):909.

12. Cui YX, Shi YC, Liu Q, Xia XY, Lu HY, Shao HF, et al. A Case of Agonadism Associated With Y-Chromosome Rearrangement: Cytogenetic and Molecular Studies. *Journal of andrology*. 2009;30(6):650-4.
13. Michala L, Goswami D, Creighton S, Conway GS. Swyer syndrome: presentation and outcomes. *BJOG: An International Journal of Obstetrics & Gynaecology*. 2008;115(6):737-41.
14. Hughes IA, Werner R, Bunch T, Hiort O, editors. *Androgen insensitivity syndrome. Seminars in reproductive medicine*; 2012: Thieme Medical Publishers.
15. Hughes IA, Houk C, Ahmed SF, Lee PA. Consensus statement on management of intersex disorders. *Journal of pediatric urology*. 2006;2(3):148-62.

How to cite:

Gholizadeh M.A., Bazgir A., Sarvar F., Pakzad Z. A female with 46,XY Disorder of Sexual Development with normal SRY gene sequence: A case report. *Jorjani Biomedicine Journal*. 2019; 7(1): 14-21.